

CASE REPORTS

Laparoscopic treatment of a vesico-vaginal fistula: A new approach

Antoni Llueca*, Jose Luis Herraiz, Yasmine Maazouzi, Dolors Piquer

Unit for Abdomino-Pelvic Oncology Surgery (MUAPOS), University General Hospital of Castellon; Department of Medicine, University Jaume I (UJI), Castellon, Spain

Received: May 3, 2016

Accepted: June 16, 2016

Online Published: June 23, 2016

DOI: 10.5430/css.v2n3p23

URL: <http://dx.doi.org/10.5430/css.v2n3p23>

ABSTRACT

Vesicovaginal fistulas (VVF) are among the most distressing complications of gynecologic and obstetric procedures. Management of these fistulas has been better defined and standardized over the last decade. VVF repair is most commonly repaired with transvaginal approach. We report a case of VVF which was repaired using a laparoscopic approach. The fistula was a complication of a benign laparoscopic hysterectomy. We describe a novel technique for the treatment of VVF of supratrigonal location by intraperitoneal laparoscopic approach.

Key Words: Vesicovaginal fistulas, Laparoscopy, Hysterectomy, Gynecologic complications

1. INTRODUCTION

The existence of vesicovaginal fistulas (VVF) dates from the antiquity. Mahfouz described a VVF in an Egyptian mummy dating back from 4000 B.C. while Professor Derry discovered another VVF in the mummified corpse of Queen Henhit B.C.

Although there are various etiologies for VVF, such as a post pelvic radiotherapy complication, obstetrical accidents, illegal abortions etc., the most common cause in developed countries is during a hysterectomy, regardless of the approach (vaginal, laparotomy or laparoscopic).^[1-3] Around 62%-87% of the VVF that were diagnosed in the world are considered a postoperative complication, the average age of presentation being at 52 years of age.^[4]

The prevalence of VVF in developing countries is approximately 1/1800 hysterectomies; on the other hand, there are more than 3,000,000 women in the developing countries presenting VVF, with an annual incidence of 130,000 new

cases.^[1]

Laparoscopic surgery has experienced an exponential growth, in the last two decades, due to its advantages in the intra and postoperative periods, unlike conventional surgery, and may be applied to this day in most surgical procedures.

The gold standard technique for posterior supratrigonal fistulas is the one described by O'connor,^[5] in which the fistula is accessed using a transvaginal approach. An anterior cystostomy is performed in order to get to the fistula, localized at a posterior level, and perform a complete resection.

The aim of this article is to describe a new technique for the treatment of the posterior supratrigonal VVF using an intraperitoneal laparoscopic approach.

2. CASE REPORT

A 48-year-old woman, who underwent a laparoscopic simple hysterectomy twenty days earlier due to hypermenorrea, vis-

*Correspondence: Antoni Llueca; Email: antonillueca@gmail.com; Address: Unit for Abdomino-Pelvic Oncology Surgery (MUAPOS), University General Hospital of Castellon; Department of Medicine, University Jaume I (UJI), Castellon, Spain.

its our consult describing urinary incontinence. The patient presents a transvaginal urinary escape since the immediate postoperative period, and is diagnosed with a VVF. She is subsequently treated using a laparoscopic approach, and to this day, there was no recurrence.

The patient initially came to our department due to her urinary incontinence. The physical exam however revealed a VVF. The retrograde cystography we requested revealed a fistulous connection between the bladder and the vagina in the posterobasal wall (3 cm). The diagnosis was corroborated by a pelvic CT scan, which reveals a large fistula located at the height of the trigone that is not affecting the ureter.

The VVF is repaired via laparoscopy, one month post-hysterectomy, using a technique which will now be described. The surgery lasted 90 minutes, with an intraoperative bleeding of 100 ml. The patient remained hospitalized during the following two days and initiated alimentary tolerance 12 hours postsurgery. Metamizol was used as analgesia during her hospital stay. The Foley catheter was taken out 20 days later, after having performed a cystography which showed no significant changes or recurrence.

Surgical technique

The patient is first explored under general anaesthesia and in a lithotomy position. The fistula's exit orifice in the vaginal cuff is identified and a urinary Foley catheter is introduced inside. We insufflate the globe and seal the catheter with n° 0 silk sutures. The tube is then sectioned at about 5 cm - 6 cm from the intravesical globe, leaving the end of the closed off catheter inside the vagina (see Figure 1).

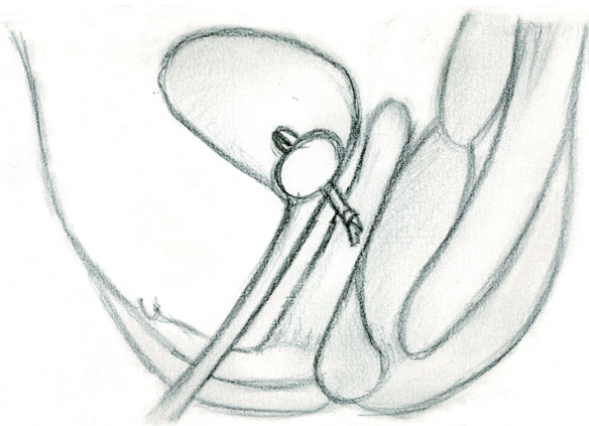


Figure 1. The Foley catheter is introduced through the fistulized tract

A vaginal plug, using gauze, is inserted in order to preserve the gas used for the laparoscopy and obtain an adequate pneumoperitoneum.

Following the preoperative preparations, the patient is moved into a supine-decubitus position and the laparoscopy intervention is initiated. A Hasson trocar is placed at the infraumbilical level and the gas is introduced. The pneumoperitoneum is achieved using CO₂ at a maximum pressure of 12 mmHg and the 0° scope is introduced. Two accessory trocars, of 5 mm, are placed at a distance of 4 cm from both anterior-superior iliac spines and another 5 mm is placed midline (5 cm above the pubic symphysis).

We decided to open the vaginal cuff, which protruded because of the pressure applied by the second assistant on the vaginal plug using Forester forceps. Once the vaginal opening is made, using monopolar energy, the end of the obstructed catheter is visualized. The urinary bladder is dissected, separating it from the anterior wall of the vagina until the end of the knotted catheter is found. We then take the end of the catheter, placing it inside the abdominal cavity, and we continue to pull it, peeling the bladder off the anterior wall of the vagina, until we reach the lower end of the fistula (see Figure 2).

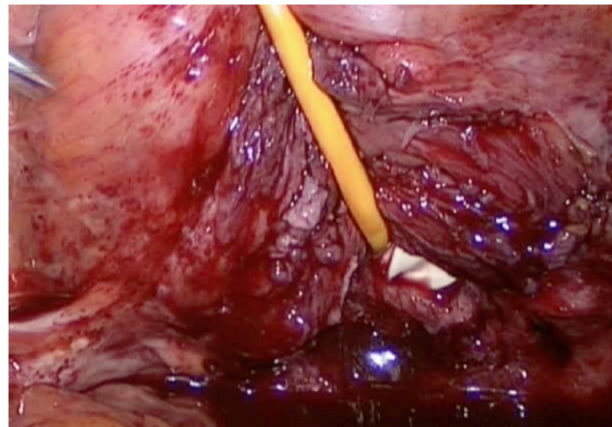


Figure 2. Colpotomy and dissection of the posterior wall pulling the Foley catheter

With this technique and by pulling on the catheter's end, the epithelized orifice of the fistula is excised using scissors, cutting the entire circumference of the bladder's fistula. Once we've verified that the fistula has been completely excized, the bladder orifice is sutured using Vicryl 2/0, in two layers, followed by the vaginal cuff, also using Vicryl 2/0 (see Figure 3). A cystoscopy is performed in order to verify the integrity of the ureter. A permanent urinary catheter is placed and maintained during 10 days, while the abdominal drain is maintained during 48 hours.

3. DISCUSSION

The first repair of the VVF is the one with the greatest effectiveness. The results will depend on the elapsed time

since the fistulous tract has been made, its etiology, the quantity of necrotic tissue present, the surgical technique and the experience of the surgeon.^[6,7] The VVF should be repaired immediately or at the latest, 24-48 hours after it has occurred. After 48 hours, the repair's effectiveness remains controversial.^[8]

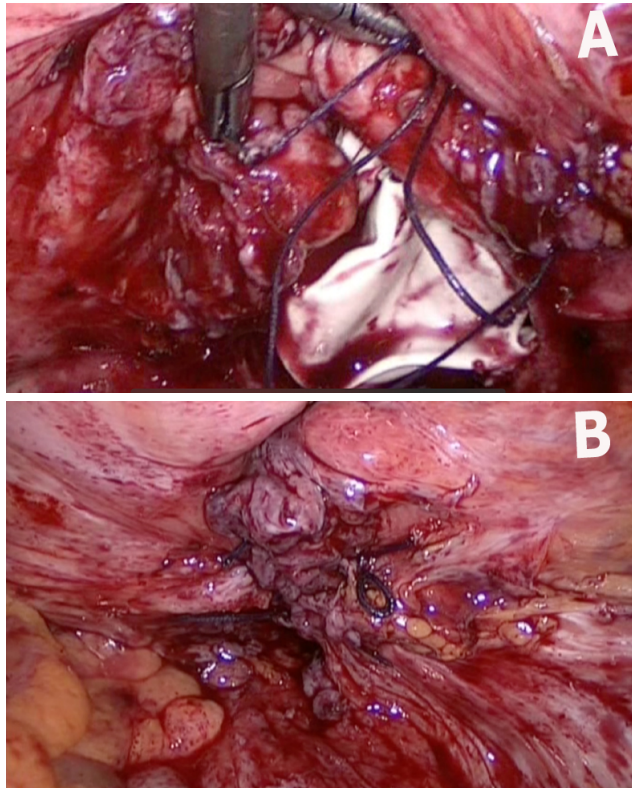


Figure 3. Suture of the colpotomy and the bladder

Our team performed the repair 40 days after the hysterectomy because it was decided that the fistula was already created, with absolute definition of the area of fibrosis around the fistula and without edema, which allowed a complete wide resection without leaving fistulous elements in the area.

An adequate exposure of the fistula, as well as a wide excision of the fistulous tissue in order to leave healthy tissue, an appropriate use of sutures, and an effective postoperative bladder emptying are required during surgery.^[9]

The approach and the technique used must be in accordance with the location and size of the fistula. Classically, infratrigonal fistulas without any associated complications can be treated using a vaginal approach. In cases of supratrigonal fistulas, located at a higher level close to the ureters, an abdominal approach is preferred,^[10] although the decision of the approach of the VVF ultimately depends on the experience of the surgeon and his team.

The laparoscopic approach is currently an alternative for many uro-gynecological procedures, and offers us a magnified surgical field with a better exposure of the fistulous tract, thorough resection of scar tissue and tension free tissue closure using intracorporeal suture. The laparoscopic approach will also offer less postoperative pain, shorter hospital stay and a better general recovery of the patient, permitting a faster return to daily tasks and activities.^[8-11]

Placing a Foley catheter via the vaginal approach, reaching the inside of the bladder through the fistula, allows the exact demarcation of the fistula and at the same time facilitates the separation between the vagina and the inferior part of the bladder. This makes the resection of the fistula easier without the need to carry out an anterior cystostomy in order to approach a fistula in a posterior location according to O'Connor's technique.

4. CONCLUSIONS

The repair of the VVF via a retrovesical laparoscopic approach is a new alternative which is safe, minimally invasive, and reproducible in trained hands. Although there are various techniques in the laparoscopic correction of VVF, it is necessary to wait for the long-term results in order to see the effectiveness of the technique we've used. It should also be used in a greater number of patients to objectively evaluate the results of this new approach.

This paper has been written with the invaluable help of the Sra Judith Mañe, who created the drawings of the surgical technique.

CONFLICTS OF INTEREST DISCLOSURE

The authors declare no conflict of interest.

REFERENCES

- [1] Laparoscopic treatment of a vesico-vaginal fistula: First case in Mexico. *Urology Mexican Association*. 2007; 2: 91-94.
- [2] Sotelo R, Mirandolino B. Laparoscopic repair of vesicovaginal fistula. *J Urol*. 2005; 173: 1615-18. PMID: 15821510. <http://dx.doi.org/10.1097/01.ju.0000154701.97539.ef>
- [3] Miller EA, Webster GD. Current management of vesicovaginal fistulae. *Curr Opin Urol*. 2001; 11: 417. <http://dx.doi.org/10.1097/00042307-200107000-00014>
- [4] Gözen AS, Teber D, Canada AE, et al. Transperitoneal laparoscopic repair of iatrogenic vesicovaginal fistulas: Heilbronn experience and review of the literature. *J Endourol*. 2009; 23(3): 475-9. PMID: 19216638. <http://dx.doi.org/10.1089/end.2008.0236>

- [5] O'Connor JR. Review of vesicovaginal fistula repair. *J Urol*. 1980; 123: 367-9.
- [6] Lee RA, Symmonds RE, Williams TJ. Current status of genitourinary fistula. *Obstet Gynecol*. 1988 Sep; 72(3 Pt 1): 313-9. PMID: 3043287.
- [7] Margolis T, Mercer LJ. Vesicovaginal fistula: review. *Obstet Gynecol Surv*. 1994 Dec; 49(12): 840-7. PMID: 7885661. <http://dx.doi.org/10.1097/00006254-199412000-00008>
- [8] Hilton P. Vesico-vaginal fistula: new perspectives. *Curr Opin Obstet Gynecol*. 2001; 13: 513. PMID: 11547033. <http://dx.doi.org/10.1097/00001703-200110000-00011>
- [9] Romics I, Kelemen Z. The diagnosis and management of vesicovaginal fistulae. *BJU Int*. 2002; 89: 764-66. PMID: 11966642. <http://dx.doi.org/10.1046/j.1464-410X.2002.02713.x>
- [10] Dos SALA, Tanaka M, de Abreu SC, et al. Laparoscopic management of iatrogenic lesions. *Journal of Endourology*. 2008; 22(6): 1279-83. PMID: 18484884. <http://dx.doi.org/10.1089/end.2008.0050>
- [11] Lluca A, Herraiz JL, Rodrigo M, et al. Intravesical mini-laparoscopic repair of vesicovaginal fistulas. *Gynecological Surgery*. 2015: 1-4. <http://dx.doi.org/10.1007/s10397-015-0913-5>